

# ABSTRACTS

## ABSTRACT #

### NEUROPROTECTIVE WRAP FOR THE SPERMATIC CORD AFTER DENERVATION PROCEDURES

Ahmet Gudeloglu, Jamin Brahmhatt, Karen Priola, Sijo Parekattil.  
Winter Haven Hospital & University of Florida

**Introduction:** Previous studies have shown that microsurgical denervation of the spermatic cord is a possible treatment option for chronic orchialgia with success rates in the 75-85% range. Recurrent or persistent pain after such procedures is very disappointing for these patients. One cause for this phenomenon could be neuroma formation or irritation of the ligated ends of the nerve fibers in the spermatic cord. Neuroprotective wraps have been safely and successfully utilized by microsurgeons in peripheral nerve repair procedures to minimize such neuroma or scar formation. This study evaluates the impact of a neuroprotective wrap placed around the spermatic cord after the denervation procedure.

**Methods:** We reviewed a prospectively maintained database of six patients with bilateral chronic orchialgia who underwent bilateral robotic assisted microsurgical denervation of the spermatic cord by a single microsurgeon from March to July 2010. A neuroprotective wrap (bio-inert matrix derived from porcine gut: Axoguard, Axogen Inc., Gainesville, FL) was placed on one side of each patient around the spermatic cord after completion of the denervation procedure (side was randomly selected). The contralateral side (with no wrap) was the control for each patient. Pain was assessed preoperatively and post-operatively at 1, 3, 6 and 12 months using an externally validated pain impact questionnaire (PIQ-6, QualityMetric Inc, Lincoln, RI).

**Results:** The median pain impact scores were less on both sides after surgery compared to pre-op (median pre-op score = 77). Median PIQ-6 scores on the wrap side were: 52, 40, 50 and 59 at 1, 3, 6 and 12 months post-op respectively. The median scores on the non-wrap side were: 59, 56, 60 and 68 respectively (Figure 1). The median pain scores on the side with the wrap were significantly less than the non-wrap side (a score difference of 5 indicates a p value of <0.05).

**Conclusion:** This study, despite its small sample size, seems to indicate a possible benefit to using a neuroprotective wrap around the spermatic cord after denervation procedures for chronic orchialgia. Further evaluation and longer follow-up is needed.

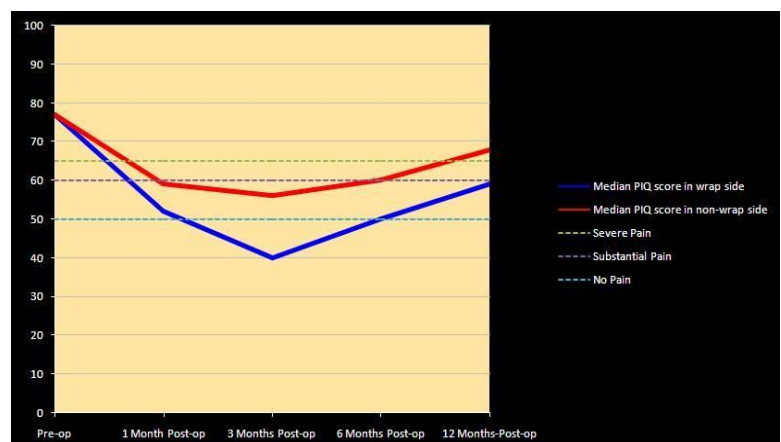


Figure 1: Pre-op and post-op median PIQ scores in the both sides.